



Blocked or Not?

By Roger Newson

Every owner's nightmare: your cat appears to have an intestinal obstruction. The symptoms are all there: loss of appetite, lethargy, apparent constipation and vomiting accompanied with a foul odor, and possibly coughing and breathing difficulties.

Ingestion of foreign objects is the most common cause, usually resulting in surgery to remove the objects and often a portion of the intestine that was actually blocked and starting to die off. Sometimes, the cause is much more sinister.

An intestinal blockage is what I suspected with my 7 week-old baby cougar, Kowe. (Kowe is short for Kowechobe, which means "panther" in the Seminole/Micosukee tongue.) Symptoms appeared the very day I brought her home after the first feeding. Upon eating, Kowe immediately regurgitated her meal of ground turkey. Then, she would re-swallow her meal and regurgitate again. This

occurred four of five times before the meal finally stayed down.

I made a quick phone call to Kowe's breeder to ascertain if the breeder had observed this eating response. The breeder assured me that there had been no previous indication of any vomiting or any other digestive problems. The breeder suggested that, perhaps, I had fed Kowe too much or allowed her to eat too quickly and that I should warm the meal before feeding.

Over the next three days this pattern continued with every meal, no matter what the portion size of the meal, the frequency of feeding, or the serving temperature. In addition, Kowe had achieved no bowel movement.

I had brought Kowe home on a Saturday afternoon, and my standard veterinarian was not available until Tuesday morning. Although I suspected that she had ingested a foreign object at some time before I brought her home, I decided to wait for professional help rather than risk aspirating

her by administering Ipecac or something similar to dislodge the foreign object. Kowe otherwise had a good appetite, appeared healthy, and had no other symptoms.

On Tuesday the veterinarian performed a complete physical and gave Kowe a clean bill of health. He suggested that I change her diet to Hills Prescription a/d as he felt that the raw ground turkey may be causing the regurgitation, since she had just recently been weaned. He believed that the colon was empty and that the ground turkey probably had a high utilization factor, hence no stool... not to worry.

Kowe continued to regurgitate every meal over the next week, including Hills Prescription a/d, which she obviously didn't care for. However, she did produce a stool six days after I brought her home.

The regurgitation became more extreme over the next few days and Kowe began to lose her appetite. In an attempt to keep her nourishment levels high, I blended the

ground turkey and supplements into a liquid paste to minimize the regurgitation. Even so, once she had ingested an ounce or two, it was repeatedly expelled.

On the following Sunday Kowe began to vomit violently, so much so that it was driven out of her nostrils, accompanied by a foul odor. This, of course, presented an ominous threat of asphyxiation and further solidified my belief that she had an intestinal blockage. I was terribly worried for my precious little Kowe.

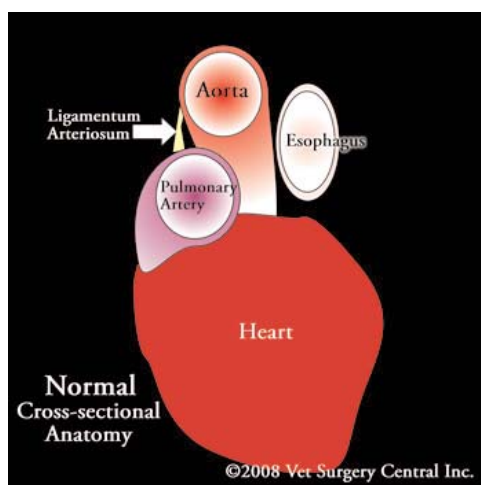
By now I had contacted a number of experienced exotic experts and several different veterinarians seeking help for Kowe. The consensus was mixed. Some believed that there was an obstruction, others did not. Blocked or not? One of the exotic owners suggested that I contact Dr. Salvatore Zeitlin, a renowned veterinary surgeon and past director of the Palm Beach Zoo.

Dr. Zeitlin agreed to see Kowe immediately on Monday morning. He gave her another complete physical and performed blood analysis. Except for the vomiting, her general health was good and her blood levels were all normal. He suggested a blockage of food passage to the stomach due to either bone or the possibility of a vascular ring anomaly.

The next step was radiology. The initial X-ray divulged an enlargement and displacement of the esophagus. Subsequent barium radiology confirmed not only a displacement of the esophagus, but also a severe distention of the esophagus indicating a stricture to the esophagus that prevented food from passing to the stomach. Consequently, the esophagus had become expanded out of shape as food built up in the esophagus rather than passing into the stomach. This explained the regurgitation immediately after eating.

Dr. Zeitlin suspected that the stricture resulted from a Persistent Right Aortic Arch (PRAA). PRAA is a congenital anomaly of the blood vessels of the heart that results in constriction of the esophagus and surgery is the only viable treatment option. The earlier the treatment is performed, the better the prognosis for survival.

The diagnosis of a PRAA is generally made from radiographs (X-rays) made after a barium swallow. The esophagus in front of the heart will appear dilated. In some cases the esophagus behind the heart will



also be dilated. This is a warning sign that the cat could have poor function of the esophagus even if surgery is performed.

Radiographs are also used to determine if the cat has concurrent pneumonia.

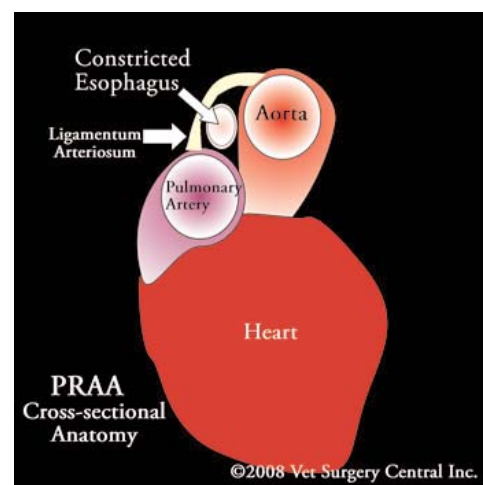
Blood testing including a complete blood count, chemistry profile, and urinalysis are recommended to make sure that the cat has healthy internal organs prior to surgery and may show signs of low blood sugar or a high white blood cell count if infection is present.

An ultrasound may also be recommended to rule out other congenital heart defects that may require attention.

Dr. Zeitlin went on to explain that during development in the uterus, the fetus has a right and left aortic arch. Normally the left aortic arch forms the main artery that extends off the heart and travels to the abdominal region. If the right aortic arch develops into the aorta, the esophagus becomes trapped and constricted by a ligament that extends from the pulmonary artery (vessel that pumps blood to the lungs) and the aorta.

In 95% of the cases of a vascular ring anomaly, a constricting band prevents solid foods from passing to the stomach which prevents the animal from getting nourishment. In the remaining 5% of cases, a bizarre anomaly of the vessels is present (double aortic arch and aberrant subclavian artery), which is very difficult to correct and presents a poor prognosis.

Usually signs are not seen until solid food is fed at the time of weaning off the mother's milk. Signs include regurgitation of food or fluid, poor nourishment, stunted growth, and signs related to pneumonia (lethargy, coughing, breathing difficulty). These animals usually have hearty



appetites, because they cannot get the nutrition that they need.

Dr. Zeitlin sent the X-ray photos to a board certified radiology specialist to confirm the diagnosis. In the meantime, he put Kowe on a strictly liquid diet of KMR milk replacement for kittens to build up her nourishment levels in preparation for surgery. Prior to surgery it is important to provide as much nutrition as possible to the cat. This may include feeding high calorie gruel. During and after feeding a meal, the cat's front end should be elevated so as to make sure that the food will pass into the stomach by means of gravity.

Kowe appeared to thrive on the liquid diet. Her appetite returned and she continued to gain weight.

In the interim, Dr. Zeitlin called me with confirmation of the diagnosis, and in an honest and straightforward manner, informed me of the inherent risks and the considerable cost involved to perform such an extensive and delicate operation. There was no guarantee that the surgery would be successful. He said that considering the economics and potential hazard involved, perhaps, euthanasia may be an appropriate course of action. I explained to Dr. Zeitlin that the moment Kowe became a part of my family, it involved a 20 year commitment to her and her health and well being and that I always keep my commitments. Surgery was scheduled for the following Thursday. Hopefully, she could withstand the effects of anesthesia and the delicate surgical procedure ahead.

On the day of surgery an intravenous catheter is placed to provide intravenous fluid therapy. Young cats are also very susceptible to developing low blood sugar. Therefore, a sugar solution is typically

incorporated in the intravenous fluids.

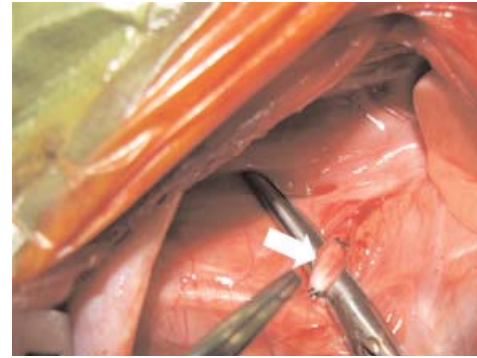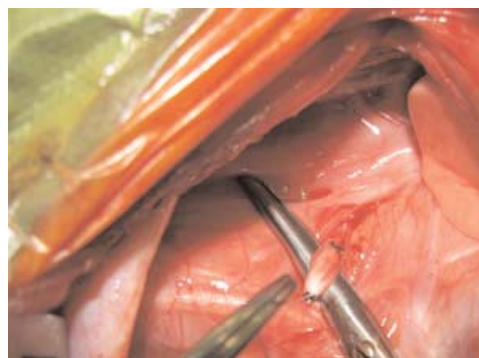
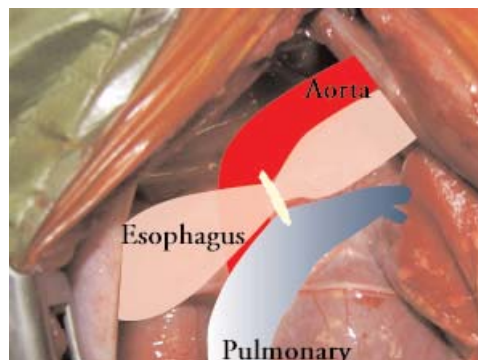
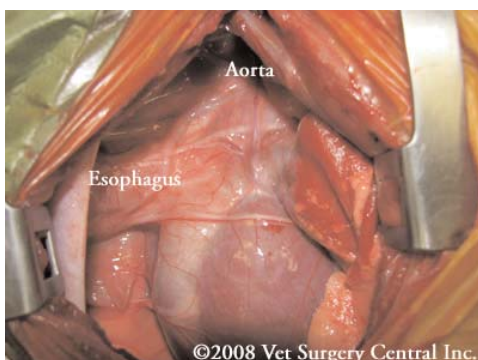
An incision is made on the left side of the chest and between the fourth and fifth ribs. They are spread to expose the covering of the heart and band (ligamentum arteriosum) constricting the esophagus. The band is readily identified by running a finger or the tip of a surgical instrument along the esophagus. The phrenic, vagus and recurrent laryngeal nerves, located near the constricting band are identified and protected during the procedure.

The constricting band is isolated using a surgical instrument, tied twice with a suture and cut. The constricting band must be tied off, as the ligamentum arteriosum frequently still is a patent vessel in very young animals. After the constricting band is cut, fibrous tissue that may be constricting the esophagus is dissected off the esophagus. A tube is placed down the mouth and through the area of the esophagus to make sure that there are no additional constrictions.

After surgery, medication is given to the cat to ensure a pain-free recovery. Intravenous fluids are commonly administered overnight or longer if indicated. Once the cat is eating and drinking well, intravenous fluids may be discontinued.

The cat may or may not have a chest tube after surgery, which is used to remove fluid and air from the chest cavity. Typically, the tube can be removed after 12 to 24 hours. Some surgeons prefer to administer pain relieving medication (local anesthetic) through the tube to numb the incision.

Elevated feedings may be required for an additional month after surgery. If the cat is no longer regurgitating, the elevated



feedings can be discontinued. Once the cat can swallow well and there is no regurgitation, solid foods can be gradually introduced.

Exercise must be restricted for three weeks after surgery so that the surgical site can heal properly.

In spite of performing the corrective surgery, some cats never regain normal motility of the esophagus and the cat will remain un nourished and likely will die.

Pneumonia is a possible problem due to aspiration of fluid that may pool in the esophagus. Infection of the surgical site is possible, but an infrequent complication.

It has been shown that cats less than 2

months of age have a much higher death rate due to anesthesia and surgery. Yet, the surgery should not be delayed too long, as permanent damage to the esophagus may occur.

Overall, about 80% of cats having early surgery to correct this condition will have resolution of the regurgitation and they thrive well. The remaining cats may do poorly and may deteriorate from the preoperative condition.

Thank God! Kowe not only survived the surgery, but is recovering very well. She is successfully eating solid foods and is gaining weight properly. She can eat a normal diet now with the exception of bone. All bone content must be fine ground for the next few weeks while her esophagus heals and gains muscle tone.

Thanks to Dr. Zeitlin for providing such tremendous skill and dedication. In addition, I wish to extend my heartfelt appreciation to the following fine folks for providing their help and expert advice to save my Kowe: Sue Arnold, Dr. Terry O'Neill, DVM, Lynn Culver, Lisa Welch, Dr. Lee Corbridge, DVM, and Pat Garvey.

Special thanks to Dr. Daniel A. Degner, board-certified veterinary surgeon (DACVS) and Vet Surgery Central, Inc. for allowing the use of their content and drawings. •

